

Transcatheter Aortic Valve Implantation with balloon-expandable valve in low-flow low-gradient severe aortic stenosis in Nepal

Chandra Mani Adhikari¹, Birat Krishna Timalsena¹, Amrit Bogati¹, Barkadin Khan¹, Anjana Acharya¹, Vijay Ghimire¹, Kshitij Mehta¹, Dipanker Prajapati¹

¹ Department of Cardiology, Shahid Gangalal National Heart Centre, Kathmandu, Nepal

Corresponding Author: Chandra Mani Adhikari

Department of Cardiology, Shahid Gangalal National Heart Centre, Kathmandu, Nepal

Email: cmadhikari@sgnhc.org.np

ORCID ID NO: 0000-0001-5811-9977

Cite this article as: Adhikari CM, Timalsena BK, Bogati A, et al. Transcatheter Aortic Valve Implantation with balloon-expandable valve in low-flow low-gradient severe aortic stenosis in Nepal. *Nepalese Heart Journal* 2023; Vol 20(1), 49-52

Submission date: 18th January, 2023

Accepted date: 12th March, 2023

Abstract

Transcatheter aortic valve implantation is the most preferred treatment of aortic stenosis in elderly patients at high surgical risk; however, few data exist on the adoption of transcatheter aortic valve implantation for the management of low-flow, low-gradient severe aortic stenosis patients. We present a recent case experience with a 77-year-old man suffering from low-flow, low-gradient, symptomatic severe aortic stenosis with concomitant coronary artery lesions in the left anterior descending and right coronary arteries. He was treated successfully with balloon-expandable transcatheter aortic valve implantation after the percutaneous coronary intervention of the left anterior descending artery and right coronary artery lesion. Post-procedural and 30-day follow-ups showed good functional and hemodynamic improvements with the mean aortic gradient of 3 mmHg (baseline: 30 mmHg) without residual paravalvular leakage. Our first experience with a balloon-expandable transcatheter valve was satisfactory as we observed clinical efficacy and good performance of the balloon-expandable transcatheter aortic valve in low-flow, low-gradient, symptomatic severe AS patients.

Keywords: Aortic Stenosis, Low-flow low-gradient aortic valve stenosis, Transcatheter aortic valve implantation

DOI: <https://doi.org/10.3126/njh.v20i1.55038>

Introduction

Globally, the healthcare burden of aortic stenosis (AS) has increased in recent decades, with aging populations in Western countries.^{1,2} In the United States, the disease affects approximately 5% of the population at the age of 65, which rises with increasing age.² Although AS has a relatively higher prevalence in Western countries,^{1,2} Lee *et al* point to its increase in China and South-East Asia that remarkably contributes to the global scenario.³ Since AS is associated with a high mortality rate,⁴ patients are usually recommended to undergo prompt treatment. According to the 2020 American College of Cardiology / American Heart Association (ACC/AHA), guidelines for the management of valvular heart disease,⁵ transcatheter aortic valve implantation (TAVI) is the class IA recommendation in patients aged between 65-80 years, suffering from severe symptomatic AS (after careful risk-assessment and valve anatomical evaluation). Therefore, there is increasing adoption of TAVI for severe symptomatic AS patients in Western countries. In contrast, the adoption of TAVI in Asian countries has been slow with very limited evidence of its use.³

With the evolution of the TAVI procedure, the devices used for TAVI underwent key design transformations, and better functional self-expandable and balloon-expandable (BE) transcatheter heart valves (THVs) came into use. The THVs available today are more compatible for shorter procedural time, which translates into better postoperative clinical outcomes among AS patients.⁶ With TAVI, it is relatively easier to return to normal life and prevent adverse

events, including mortality, in comparison to valvular repair procedures.⁶ In the Asian population, the physical attributes of AS patients are much different, including lesser body surface area and a higher prevalence of bicuspid morphology, low coronary ostial heights, higher susceptibility to bleeding events, and lower risk for thrombogenicity.³ They also have a smaller aortic annulus area and a higher prevalence of low-flow, low-gradient (LFLG) AS.^{3,7} As Per the 2020 ACC/AHA practice guidelines, severe symptomatic LFLG AS is characterized as the presence of severe leaflet calcification with reduced leaflet motion, with stroke volume index below 35 mL/m² and aortic valve area ≤ 1.0 cm² with resting maximum aortic jet velocity below 4 m/s or mean pressure gradient ≤ 40 mmHg.⁵ Such patients are recommended to undergo AVR since they generally have a high surgical risk.

Normally, an interventional cardiologist selects a valve depending on the patient's clinical characteristics, which includes the suitability of aortoiliac-femoral access and distribution of calcium extending to the left ventricular outflow tract (LVOT).⁸ The CE-marked, newer-generation, balloon-expandable Myval Transcatheter Heart Valve (THV) (Meril Life Sciences Pvt. Ltd. India) has shown clinical efficacy and safety in previous studies, including the MyVal-1 trial.⁹ The MyVal-1 study reported successful TAVI outcomes of 30 intermediate- to high-risk patients with no paravalvular leaks or post-procedural permanent pacemaker implantation.⁹ Another recent study demonstrates favorable results of Myval THV implantation in 100 low-risk AS patients with acceptable 30-day hemodynamic outcomes.¹⁰

Based on the earlier evidence of BE Myval THV showing good clinical outcomes in different populations,^{11,12,13} we present our first experience of the management of a patient with LFLG severe symptomatic AS undergoing TAVI using BE Myval THV at a South-Asian center.

Case Report

A 77-year-old male having symptomatic LFLG severe AS (stage D2/3)⁸ presented to our hospital for consultation after being admitted and treated medically at another center for dyspnea and syncope. ECG showed a normal sinus rhythm with poor progression of the R wave. The echocardiographic assessment revealed a severe degenerated tricuspid aortic valve with low-flow (peak aortic velocity = 3.3 m/s) and low-gradient (peak pressure gradient \approx 44 mmHg and mean pressure gradient = 30 mmHg), severe AS with a calculated aortic valve area of 0.6 cm². The patient had a reduced left ventricular ejection fraction (LVEF 35%), indicating hypokinesia in the left anterior descending (LAD) territory.

The coronary angiogram revealed double vessel disease with total occlusion of the mid-LAD and significant stenosis of the mid-right coronary artery (RCA). Thorough visualization of the occluded territories was obtained by cardiac magnetic resonance imaging, which revealed viable LAD and RCA territories. On multi-slice computed tomography (MSCT), the mean aortic annulus diameter was 23.9 mm, the annulus perimeter was 75 mm, the sinus of Valsalva's mean diameter was 26.6 mm, and the annulus area was 434.6 mm². The right and left coronary ostial heights were 15.7 mm and 13.7 mm, respectively. Mild aortic valve calcification was noted. The average diameters of the right common iliac (9.9 mm), external iliac (8.7 mm), and femoral (8.6 mm) arteries were observed to be normal. Based on the aortic root analysis by MSCT, a 24.5 mm BE Myval THV was selected.

The choice of treatment options and their benefits was discussed with the patient, including CABG and surgical AVR (SAVR), but the patient opted for percutaneous coronary intervention (PCI) followed by TAVI. Written informed consent was obtained from the patient and his family for both procedures.

A comprehensive heart team assessment was performed, which included a cardiac surgeon, anesthesiologist, and cardiologist, who checked all the prerequisites of the interventional procedures. Prior to the procedure, an operation theatre was set up to be used in case of an emergency conversion to an open procedure. The team comprised five cardiologists, two cardiac anesthesiologists, one cardiac surgeon, three catheterization laboratory nurses, and one interventional radiology technician.

First, PCI to LAD and RCA was performed successfully through the right radial route with the implantation of a drug-eluting stent. The patient then underwent TAVI under local anesthesia and under intraoperative transthoracic echocardiography (TTE) imaging guidance. The right and left femoral arteries and right femoral vein were cannulated. A temporary pacemaker was placed in the right ventricle through the right femoral vein access. The left femoral artery was used to introduce a 6 Fr pigtail catheter through a 6 Fr sheath into the noncoronary sinus as a marker for valve placement and to allow arteriography for positioning. The right femoral artery was used to deliver the THV. Once all arterial and venous accesses were achieved, intravenous unfractionated heparin was administered to achieve a recommended activated clotting time of >250 s. The right femoral artery access was used for proceeding a J-tipped, soft 0.035 mm wire into the descending thoracic aorta and a single suture-mediated closure device (Perclose ProGlide, Abbott Cardiovascular, Abbott Park, IL, USA) was deployed for pre-closure after the procedure while maintaining the arterial access through the J-tipped guidewire. Subsequently, 14 Fr Python expandable introducer sheath (Meril Life Sciences Pvt. Ltd. India) was advanced into the femoral artery. A 6 Fr AL-1 catheter was passed through the valve delivery sheath over a 145–150 cm 0.035-inch J-tipped

guidewire and exchanged for a straight-tip wire to cross the valve. Once across, the straight-tip wire was exchanged for a 300 cm J-tipped wire. The AL-1 catheter was then removed and exchanged for a 6 Fr angled pigtail catheter. A reshaped stiff guidewire SAFARI 2™ (Boston Scientific, Marlborough, MA, USA) was then advanced through the pigtail catheter into the left ventricle, with the transition point of the guidewire held above the apex, pointing away from the ventricular wall. A 24.5 mm BE Myval THV was implanted as under a pacing of 180 beats/min shown in figure 1. The valve positioning was checked by obtaining a root aortogram using a pigtail catheter before and after deployment. The BE Myval THV was positioned 5 mm below the native annulus. The root aortogram and coronary angiography visualized an optimal positioning of the bioprosthesis as shown in figure 2.

The immediate post-deployment TTE showed a good position, normal leaflet motion, no paravalvular leakage, and a mean pressure gradient reduced to 3 mmHg. While maintaining the wire position, the ProGlide closure device was deployed, and protamine was administered. Following successful valve implantation, the introducer sheath, catheter, and guidewires were removed. The patient was transferred to the cardiac intensive care unit. The postoperative recovery period was uneventful, and the echocardiography before discharge showed good prosthetic valve function with a mean aortic gradient of 3 mmHg without residual paravalvular leakage. The patient was discharged on postoperative Day 5. On 30-day follow-up, the patient had a good general physical condition and showed improvement up to the functional status - New York Heart Association (NYHA) class I.

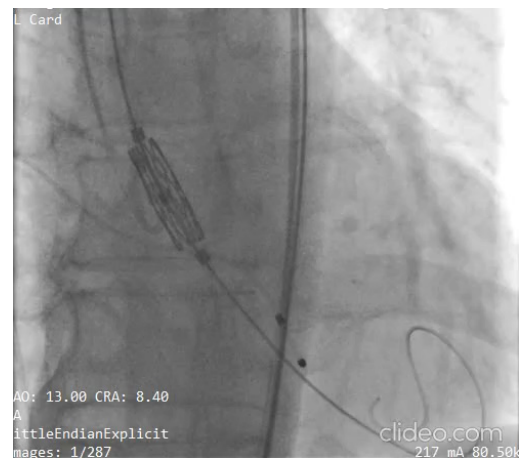


Figure 1: Positioning the Myval THV inside the aortic annulus

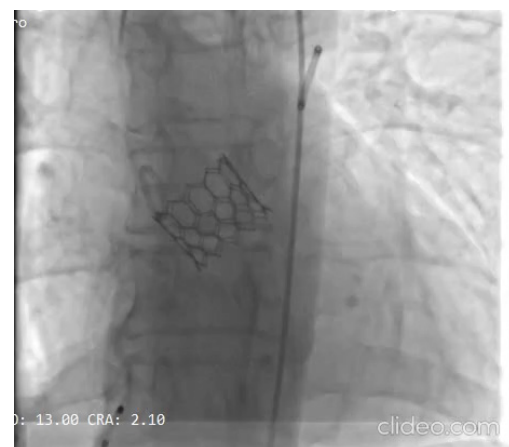

Figure 2: Fluoroscopic image shows the optimal deployment of the Myval THV

Discussion

As supported by the 2020 ACC/AHA current practice guideline, aortic valve replacement (AVR) is the class IA recommendation for LFLG severe symptomatic AS.⁵ Takagi et al conducted a meta-analysis of randomized trials on the mortality rates of SAVR versus TAVI and reported that TAVI improves the 30-day and one-year all-cause mortality in comparison to SAVR for AS patients.¹⁴

While high-gradient AS is the classical indication for TAVI, the prevalence of LFLG AS is increasing among Asian patients undergoing TAVI.¹⁵ When the mean pressure gradient is ≤ 40 mmHg and the computed aortic valve area is less than 1.0 cm², low gradient AS is diagnosed.^{5,16} In the past decade, it has been shown that early postoperative mortality in these patients may reach up to 20% after SAVR.^{7,18} A recent meta-analysis showed that both SAVR and TAVI are associated with significant reductions in all-cause mortality, compared with conservative management in all subclasses of LFLG AS.¹⁸ TAVI was associated with good periprocedural outcomes in patients with LFLG AS. However, the findings from the TOPAS-TAVI registry revealed the death of approximately one-third of LFLG-AS patients after the 2-year follow-up, with pulmonary disease, anemia, and residual paravalvular leaks following TAVI.¹⁹ A meta-analysis by Ueyama H, *et al* on the comparison of outcomes of SAVR versus TAVI in LFLG patients revealed that although both SAVR and TAVI are associated with a decrease all-cause mortality in all sub-classes of this patient subset, the extent of the reduction by TAVI is not superior to that by SAVR in patients with LFLG AS.¹⁸ Nevertheless, the less invasive nature of TAVI may offer the scope to improve outcomes of patients with LFLG severe symptomatic AS, who are generally at high surgical risk.

Careful preprocedural planning prior to TAVI is required for a successful procedure. The goals of preprocedural planning are to assess the optimal method of access; define anatomic relationships between the aortic valve, root, left ventricle, and coronary ostia; choose the optimal device size; and, lastly, contribute to the procedural plan. The choice between BE and self-expandable valves depends on the patient's characteristics and the operator's experience. Pertinent considerations include the level of comorbidities in the patient, the patient's aortoiliac-femoral access and calcium distribution in the LVOT, the size of the aortic annulus, the sinus of Valsava, and the coronary ostial height. The sizing considerations also include the calculation of the annulus perimeter and the dimensions of the sinotubular junction.^{9,12,19} As reported by Lee et al, in Asian populations, these aortic valve parameters have slight differences in comparison to their European and American counterparts.³ Self-expandable valves are more frequently associated with post-procedural aortic regurgitation and the requirement for a permanent pacemaker implant, but they may be preferable in patients with significant LVOT calcification and inadequate peripheral access.⁹ AS with concomitant CAD is associated with a worse prognosis, especially for LFLG cases.²⁰ Following PCI, TAVI with a BE Myval THV was performed in our patient, considering the presence of CAD.

The device used for TAVI in this study has been comprehensively evaluated in low, intermediate, and high surgical-risk patients.^{11,12} In the MyVal-1 study, the clinical efficacy and safety of this bioprosthetic valve were evaluated in a cohort of 30 intermediate-risk or high-risk patients with severe symptomatic AS. The trial documented procedural success and the absence of any cases of paravalvular leaks or post-procedural permanent pacemaker implantations until the 12-month follow-up.⁹ The BE Myval THV received approval from the Central Drugs Standard Control Organization (CDSCO) and Drug Controller General of India (DCGI) in 2018,⁹ and is Conformité Européenne (CE)-marked. The THV design of BE Myval ensures its accurate positioning and deployment in the precise landing zone.²⁰ Presence of light and dense banding patterns with fluoroscopic markers enables accurate positioning. The device has a wide size matrix accommodating conventional sizes

as well as intermediate sizes (21.5, 24.5, and 27.5 mm) and extra-large sizes (30.5 and 32 mm), which aid in avoiding complications associated with excessive oversizing and under-sizing, including major paravalvular leakage and residual aortic regurgitation.¹¹ As regards to long-term prevention of annular rupture, it is important to maintain a ratio of 10-15% between the prosthetic device and the native aortic annulus.^{11,21}

The patient, in this case, had pertinent risk factors such as advanced age, coexisting CAD, and a reduced LVEF, which are crucial determinants for choosing to BE THVs and deciding the need for TAVI. Therefore, TAVI following PCI was offered as the suitable treatment, which was performed without any complications. The patient is in good general physical condition at the 30-day follow-up and was reported with an improved functional status of NYHA class I without any evidence of paravalvular leak or conduction abnormalities. We ascertain that complete equipment was available with a dedicated heart team, which along with the necessary preparation for unwanted complications, ensured a successful outcome.

Conclusion:

The case report demonstrates the successful completion of a TAVI procedure with intermediate-size BE Myval THV in high-risk elderly patients suffering from LFLG severe symptomatic AS. Effective valve performance with maintained hemodynamics and improved functional NYHA class at 30 days has added to our first experience with BE THV.

Conflicts of Interest

The authors have no conflicts of interest to declare.

References

1. Ancona, R. & Pinto, S. C. Epidemiology of aortic valve stenosis (AS) and of aortic valve incompetence (AI): is the prevalence of AS/AI similar in different parts of the world? *European Society of Cardiology*. 2020;18:10 – 12.
2. Wilson, J. B. et al. Racial and Ethnic Differences in Treatment and Outcomes of Severe Aortic Stenosis. *JACC Cardiovasc Interv*. 2020; 13:149–156. 10.1016/j.jcin.2019.08.056
3. Lee, C. H., Inohara, T., Hayashida, K. & Park, D.-W. Transcatheter Aortic Valve Replacement in Asia. *JACC: Asia*.2021;1(3):279–293. <https://doi.org/10.1016%2Fj.jacasi.2021.10.006>
4. Otto, C. M., Lind, B. K., Kitzman, D. W., Gersh, B. J., Siscovick, D. S. Association of Aortic-Valve Sclerosis with Cardiovascular Mortality and Morbidity in the Elderly. *New England Journal of Medicine*.1999; 341(3):142–147.10.1056/NEJM199907153410302.
5. Catherine M Otto, Rick A Nishimura, Robert O Bonow, Blase A Carabello, John P Erwin 3rd, Federico Gentile, Hani Jneid, Eric V Krieger, Michael Mack, Christopher McLeod, Patrick T O'Gara, Vera H Rigolin, Thoralf M Sundt 3rd, Annemarie Thompson, Christopher Toly. Otto, C. M. et al. 2020 ACC/AHA Guideline for the Management of Patients With Valvular Heart Disease. *J Am Coll Cardiol* 2021;77(4):e25-e197. 10.1016/j.jacc.2020.11.018.
6. Adhikari C M, Acharya K, Bogati A, et al. Transcatheter Closure of Atrial Septal Defect and Balloon Pulmonary Valvuloplasty with Inoue Balloon in Adult Patients. *Nepalese Heart Journal* 2021; Vol 18 (1): 61-64. <https://doi.org/10.3126/njh.v19i1.45308>

7. K.K. Poppe, R.N. Doughty, J.M. Gardin, F.D.R. Hobbs, J.J.V. McMurray, et al. Ethnic-Specific Normative Reference Values for Echocardiographic LA and LV Size, LV Mass, and Systolic Function. *JACC Cardiovasc Imaging* 2015;8(6):656–665. <https://doi.org/10.1016/j.jcmg.2015.02.014>
8. Renker, M. Kim, W.-K. Choice of transcatheter heart valve: should we select the device according to each patient's characteristics or should it be "one valve fits all"? *Ann Transl Med* 2020;8:961–961. 10.21037/atm.2020.04.13
9. Sharma, S. K. Ravinder Singh Rao, Praveen Chandra, Pravin Kumar Goel, Prashant Bharadwaj, et al. First-in-human evaluation of a novel balloon-expandable transcatheter heart valve in patients with severe symptomatic native aortic stenosis: the MyVal-1 study. *EuroIntervention* 2020;16(5):421–429 (2020). 10.4244/EIJ-D-19-00413
10. Mario García-Gómez Jose Raúl Delgado-Arana Jonathan Halim, Federico De Marco, Carlo Trani, et al. Next-generation balloon-expandable Myval transcatheter heart valve in low-risk aortic stenosis patients. *Catheterization and Cardiovascular Interventions* 2022;99(3):889–895. 10.1002/ccd.29923
11. Hideyuki Kawashima, Patrick W Serruys, Darren Mylotte, Liesbeth Rosseel, Ignacio J Amat-Santos, et al. Operator preference and determinants of size selection when additional intermediate-size aortic transcatheter heart valves are made available. *Int J Cardiol* ;338:168–173. 10.1016/j.ijcard.2021.06.029
12. Jose R Delgado-Arana, María X Gordillo-Monge, Jonathan Halim, Federico De Marco, Carlo Trani, et al. Early clinical and haemodynamic matched comparison of balloon-expandable valves. *Heart* 2022; 108(9):725-732 (2022). 10.1136/heartjnl-2021-319349
13. Monica Barki, Alfonso Ielasi, Andrea Buono, Gabriele Maliandi, Mariano Pellicano, et al. Clinical Comparison of a Novel Balloon-Expandable Versus a Self-Expanding Transcatheter Heart Valve for the Treatment of Patients with Severe Aortic Valve Stenosis: The EVAL Registry. *Journal of Clinical Medicine*.202 11(4), 959. 10.3390/jcm11040959
14. H. Takagi, Y. Hari, K. Nakashima, T. Kuno, T. Ando, and ALICE (All-Literature Investigation of Cardiovascular Evidence) Group. Mortality after transcatheter versus surgical aortic valve replacement: an updated meta-analysis of randomized trials. *Netherlands Heart Journal*. 2020;28(6):320–333. 10.1007/s12471-020-01378-1
15. Sung-Han Yoon, Jung-Min Ahn, Kentaro Hayashida, Yusuke Watanabe, Shinichi Shirai, Hsien-Li Kao et al. Clinical Outcomes Following Transcatheter Aortic Valve Replacement in Asian Population. *J Am Coll Cardiol Intv*. 2016;9(9):926–933. 10.1016/j.jcin.2016.01.047
16. Helmut Baumgartner, Judy Hung, Javier Bermejo, John B Chambers, Thor Edvardsen, Steven Goldstein, Patrizio Lancellotti, Melissa LeFevre, Fletcher Miller Jr, Catherine M Otto. Recommendations on the echocardiographic assessment of aortic valve stenosis: a focused update from the European Association of Cardiovascular Imaging and the American Society of Echocardiography. *J Am Soc Echocardiogr*. 2017; 30(4):372-392. 10.1016/j.echo.2017.02.009.
17. Hiroki Ueyama, Toshiaki Kuno, Matthew Harrington, Hisato Takagi, Parasuram Krishnamoorthy, Samin K Sharma, Annapoorna Kini, Stamatios Lerakis. Impact of Surgical and Transcatheter Aortic Valve Replacement in Low-Gradient Aortic Stenosis. *JACC Cardiovasc Interv*. 2021 ;14(13):1481-1492. 10.1016/j.jcin.2021.04.038
18. Christophe Tribouilloy, Franck Lévy, Dan Rusinaru, Pascal Guéret, Hélène Petit-Eisenmann, Serge Baleynaud, Yannick Jobic, Catherine Adams, Bernard Lelong, Agnès Pasquet, Christophe Chauvel, Damien Metz, Jean-Paul Quéré, Jean-Luc Monin. Outcome after aortic valve replacement for low-flow/low-gradient aortic stenosis without contractile reserve on dobutamine stress echocardiography. *J Am Coll Cardiol*. 2009;53(20):1865-1873. 10.1016/j.jacc.2009.02.026
19. Henrique Barbosa Ribeiro, Stamatios Lerakis, Martine Gilard, João L Cavalcante, Raj Makkaret al. Transcatheter Aortic Valve Replacement in Patients With Low-Flow, Low-Gradient Aortic Stenosis. *J Am Coll Cardiol* 2018;71(12):1297–1308. 10.1016/j.jacc.2018.01.054
20. Gunasekaran Sengottuvelu, Vijay Kumar, Ashok Seth. The Myval Transcatheter Heart Valve System for the Treatment of Severe Aortic Stenosis – Current Evidence and Future Directions. *Heart Int* 2020;14(2):86-91.10.17925/HI.2020.14.2.86
21. Samin K Sharma, Ravinder S Rao, Manik Chopra, Anmol Sonawane, John Jose, Gunasekaran Sengottuvelu. Myval transcatheter heart valve system in the treatment of severe symptomatic aortic stenosis. *Future Cardiol*. 2021;17(1):73–80. 10.2217/fca-2020-0020