

# Angiographic Significance of ST Depression in Anterior Leads in Acute Inferior ST Elevation Myocardial Infarction

Rabindra Simkhada<sup>1</sup>, Barkadin Khan<sup>1</sup>, Sanjay Singh KC<sup>1</sup>, Arjun Budhathoki<sup>2</sup>, Krishna Chandra Adhikari<sup>2</sup>, Bishow Raj Baral<sup>2</sup>

<sup>1</sup>Department of Cardiology, Shahid Gangalal National Heart Centre, Kathmandu, Nepal.

<sup>2</sup>Department of Cardiology, National Academy of Medical Sciences, Kathmandu, Nepal.

**Corresponding Author:** Rabindra Simkhada

Department of Cardiology, Shahid Gangalal National Heart Centre, Kathmandu, Nepal. Phone: 9841249210

**Email:** rsimkhada2001@yahoo.com

**ORCID ID NO:** 0000-0002-3704-0175

**Cite this article as:** Simkhada R., Kahn B., KC S S., et al. Angiographic Significance of ST Depression in Anterior Leads in Acute Inferior ST Elevation Myocardial Infarction. Nepalese Heart Journal 2021; Vol 18(2), 7-10.

**Submission date:** 1st July, 2021

**Accepted date:** 3rd September, 2021

## Abstract

**Background and aims:** Electrocardiogram of acute ST elevation inferior myocardial infarction can show concomitant ST depression in anterior leads. We aimed to see its significance on coronary angiogram.

**Methods:** Cross sectional study conducted in Department of Cardiology of Shahid Gangalal National Heart Centre from March 2021 to June 2021. Total of 64 patients of acute inferior myocardial infarction were included consecutively. Electrocardiogram were analyzed for the presence of ST depression in anterior leads (V1-V6). Coronary angiogram were obtained. Linear regression analysis was applied to see correlations.

**Results:** Thirty-four (53.12%) participants had significant ST depression in anterior leads. Their mean age was 64.53±11.67 years. Twenty-two (64.70%) were male. Out of them, 13 (38.23%) were hypertensive, 9 (26.47%) were smoker and 7 (20.58%) were diabetic. Among 30 (46.88%) participants without ST depression, mean age was 56.73±13.31 years and 21 (70%) were male. Out of them, 11 (36.66%) were hypertensive, 12 (40%) were smoker and 11 (33.66%) were diabetic. Culprit vessel was right coronary artery in 22 (64.70%) of those with ST depression and 22 (73.33%) of those without ST depression. Significant left anterior descending artery lesion was seen in 19 (55.88%) of those with ST depression and 3 (10%) of those without depression. Anterior ST depression showed positive correlation with left anterior descending artery lesion.

**Conclusion:** ST depression in anterior leads in acute inferior myocardial infarction can be due to presence of concomitant left anterior descending coronary artery disease.

**Keywords:** Acute inferior myocardial infarction; Coronary angiogram; Electrocardiogram.

DOI: <https://doi.org/10.3126/njh.v18i2.40387>

## Introduction

Acute ST elevation myocardial infarction (STEMI) is one of the major public health problem in both industrialized and developing world and is the important cause of morbidity and mortality worldwide.<sup>1</sup> Recognizing the disease timely and precisely is always rewarding. Acute inferior STEMI is an important type of acute myocardial infarction (MI). An electrocardiogram (ECG) of acute inferior STEMI shows ST elevation in inferior leads and can show ST depression in anterior leads (V1-V6).

Variations exists on the angiographic significance as well as on the prevalence of traditional risk factors of those with anterior ST depression in acute inferior STEMI in previous studies done in various settings.<sup>2,3</sup> Some studies have shown that presence of anterior ST depression can be more symptomatic, can have higher severity

of the disease and increased mortality but others reported almost similar prognosis.<sup>4,5,6</sup> Since ECG is a very important and readily available tool for diagnosis of MI, understanding the significance of ST depression in anterior leads in inferior MI with reference to coronary angiogram (CAG) would help in better understanding of the disease.

We aimed to study the angiographic significance of ST depression in anterior leads in acute inferior STEMI. We also compared the prevalence of traditional risk factors between those with and without ST depression in anterior leads among the patients of acute inferior STEMI in our set up, which will help in their better management in future.

## Methods

This was a cross sectional study conducted at the department of Cardiology, Shahid Gangal National Heart Centre (SGNHC), Kathmandu Nepal from March 2021 to June 2021. The study was conducted after getting approval from institutional review board (IRB) of SGNHC. Informed consent was taken from all the participants. Adult patients of age 18 years and above with characteristic symptoms of acute MI with ST elevation of 0.1 mv or more above the TP segment measured 80 ms after the J point in 2 or more of the inferior (II, III, aVF) leads, who were diagnosed as acute inferior STEMI were enrolled consecutively during the study period. All ECGs were recorded at speed of 25 mm / sec. Doubtful diagnosis, those whose complete coronary angiogram were not available, known old myocardial infarction, presence of bundle branch block or left ventricular hypertrophy, taking medicines that can have effect on ST changes and who did not opt for consent for participation voluntarily were excluded.

History was taken focusing cardiovascular risk factors including hypertension (HTN), diabetes (DM), smoking, dyslipidemia and family history of cardiovascular disease (CVD). The 1st ECG of the participants with ST elevation in inferior leads were analyzed for presence or absence of ST depression in anterior leads. Significant ST depression was defined as  $\geq 0.1$  mv horizontal or downward ST segment depression measured at 80 ms after J point in  $> 1$  leads from V1-V6. Transthoracic echocardiogram was done and left ventricular ejection fraction (LVEF) was obtained. Coronary angiogram of the participants was reviewed to assess the coronary artery involvement. Culprit vessel for acute inferior STEMI was identified. Presence or absence of significant disease in other vessels were noted. Lesions with  $\geq 70\%$  luminal diameter stenosis was considered significant. Coronary artery disease was classified as single vessel disease (SVD) if one of the 3 coronary artery, whether right coronary artery (RCA) or left anterior descending (LAD) or left circumflex (LCX) artery was involved, double vessel disease (DVD) if 2 of the coronary arteries were involved and triple vessel disease (TVD) if all 3 arteries were involved. Gathered information were recorded in proforma for source of data.

Data entry and analysis were done in statistical package for the social sciences (SPSS) version 20. Numerical variables were described as Mean  $\pm$  Standard Deviation (SD) and categorical variables were described as frequency and percentage. Comparisons between groups with and without ST depression in anterior leads were done using multiple linear regression analysis to see the independent contribution of the variables be tested. R value were calculated to find strength of correlation. P values were calculated and considered significant if  $< 0.05$ .

## Results

Age of the participants ranged from 33 to 85 years and mean age was  $60.64 \pm 12.71$  years. A total of 43 (67.18%) were male. Among the participants, 24 (37.50%) were hypertensive, 18 (28.12%) were diabetic, 12 (18.75%) had dyslipidemia. A total of 21 (32.81%) were smoker and 8 (12.50%) had family history of CVD. A total of 34 (53.12%) had significant ST depression in anterior leads. Their mean age was  $64.53 \pm 11.67$  years and 22 (64.70%) were male. Out of those with ST depression 13 (38.23%) were hypertensive, 9 (26.47%) were smoker, 7 (20.58%) were diabetic, 6 (17.64%) had dyslipidemia and 2 (5.88%) had family history of CVD. Among 30 (46.88%) participants without significant anterior ST depression, mean age was  $56.73 \pm 13.31$  years and 21 (70%) were male. Out of them, 11 (36.66%) were hypertensive, 12 (40%) were smoker, 11 (36.66%) were diabetic 6 (20%) had dyslipidemia and 6 (20%) had family history of CVD. Traditional risk factors of participants are shown in table 1.

**Table1:** Traditional factors of CVD of participants.

Risk factors	Total participants, N=64	With ST depression, N=34	Without ST depression, N=30
Hypertension	24 (37.50%)	13 (38.23%)	11 (36.66%)
Smoking	21 (32.81%)	9 (26.47%)	12 (40%)
Diabetes	18 (28.12%)	7 (20.58%)	11 (36.66%)
Dyslipidemia	12 (18.75%)	6 (17.64%)	6 (20%)
Family history of CVD	8 (12.50%)	2 (5.88%)	6 (20%)

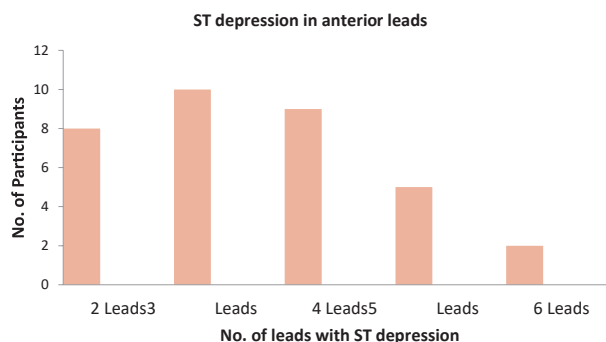
The mean ST elevation in leads II, III and aVF of all participants were  $1.42 \pm 1.04$  mv,  $2.44 \pm 1.37$  mv and  $1.90 \pm 1.29$  mv respectively and total mean ST elevation (II+III+ aVF) was  $5.77 \pm 3.47$  mv which is shown in table 2.

**Table 2:** ST elevation in inferior leads.

ECG findings	Mean $\pm$ SD
ST elevation II (mv)	$1.42 \pm 1.04$
ST elevation III (mv)	$2.44 \pm 1.37$
ST elevation aVF (mv)	$1.90 \pm 1.29$
Total ST elevation (II+III+ aVF mv)	$5.77 \pm 3.47$

Total ST depression of those 34 patients ranged from 0.25 mv to 1.90 mv with mean of  $0.68 \pm 0.42$  mv. Eight (12.50%) patients had ST depression in 2 leads, 10 (15.62%) had ST depression in 3 leads, 9 (14.06%) had ST depression in 4 leads, 5 (7.81%) had ST depression in 5 leads and 2 (3.12%) had ST depression in all 6 precordial leads. Number of leads with significant ST depressions is shown in figure 1.

Figure 1: Numbers of leads with ST depression.



Trans-thoracic Echocardiography revealed LVEF ranging from 30% to 55% with mean LVEF of  $46.33 \pm 4.89\%$ . Those with ST depression in anterior leads had mean LVEF of  $44.85 \pm 5.14\%$  (Range 30%-50%) where as those without anterior ST depression had mean LVEF of  $48 \pm 4.06\%$  (Range 40%-55%)

In overall participants, CAG revealed RCA as culprit vessel in 44 (68.75%) and LCX in 20 (31.25%). Single vessel disease was present in 26 (40.62%), DVD in 34 (53.12%) and TVD in 4 (6.25%). Significant LAD artery lesion was seen in 22 (34.37%) participants. Among those with precordial ST depression, RCA culprit lesion was in 22 (64.70%), LCX culprit lesion was in 12 (35.29%), SVD was seen in 8 (23.52%), DVD in 22 (64.70%), and TVD in 4 (11.76%). Among those without precordial ST depression, RCA culprit lesion was in 22 (73.33%), LCX culprit lesion was in 8

(26.66%), SVD was in 18 (60%) and DVD in 12 (40%). A total of 19 (55.88%) of those with precordial ST depression had significant LAD lesion while 3 (10%) of those without precordial ST depression had LAD lesion. Summary of CAG findings is shown in table 3.

**Table 3:** Coronary angiogram findings of acute inferior wall MI.

CAG Characteristics	Total Participants, N=64	With ST depression, N=34	Without ST depression, N=30
Culprit vessel RCA	44 (68.75%)	22 (64.70%)	22 (73.33%)
Culprit Vessel LCX	20 (31.25%)	12 (35.29%)	8 (26.66%)
SVD	26 (40.62%)	8 (23.52%)	18 (60%)
DVD	34 (53.12%)	22 (64.70%)	12 (40%)
TVD	4 (6.25%)	4 (11.76%)	0 (0%)
LAD lesion	22 (34.37%)	19 (55.88%)	3 (10%)

Multiple linear regression analysis showed positive correlation of anterior ST depression with sum of ST elevation in inferior leads and with LAD lesion ( $R=0.67$ ). Other variables showed no significant correlation between presence and absence of ST depression in anterior leads in patients with acute inferior STEMI. Correlation of variables are shown in table 4.

**Table 4:** Correlation between presence and absence of anterior ST depression in inferior STEMI.

Variables	P value
Age	0.08
Sex	0.34
HTN	0.85
DM	0.11
Smoking	0.14
Dyslipidemia	0.41
Family history	0.31
Total ST elevation	0.02
LVEF	0.25
No. of vessels involved	0.82
Culprit vessel	0.41
LAD Lesion	0.02

## Discussion

Mean age of participants in this study was  $60.64 \pm 12.71$  years and almost two third of them were male. We found traditional risk factors of CVD commonly. A total of 37.50% were hypertensive, 28.12% were diabetic, 18.75% had dyslipidemia, 32.81% were current smoker and 12.50% had family history of CVD. In the present study there was ST depression in anterior leads in 53.12%. Multiple linear regression analysis showed positive correlation of ST depression in anterior leads with sum of ST elevation in inferior leads and there was also positive correlation of ST depression in

anterior leads with LAD coronary artery lesion. Other variables showed no significant correlation between presence and absence of anterior ST depression.

Birnbaum and colleagues found mean age of  $59.6 \pm 11.9$  years and male gender of 77.1% in similar patients of acute inferior wall myocardial infarction. They found 33.3% hypertensive, 18.9% diabetic and 44.2% current smokers.<sup>7</sup> In a similar study by Abbas and colleagues, 37.5% of the patients were hypertensive and 30% patients were diabetics.<sup>8</sup> In a study by Gibson and colleagues ST depression in precordial leads were noted in 56% of the patients which was in consistence with our findings.<sup>2</sup> In a study by Herlitz and colleague 64% of participants had anterior ST depression.<sup>9</sup>

Our finding of positive correlation of ST depression in anterior leads with sum of ST elevation in inferior leads was similar to that of Herlitz and colleagues who reported those with anterior ST depression had greater mean ST elevation in inferior leads (II, III, aVF).<sup>9</sup> Khalil and colleagues also found mean ST segment elevation significantly higher in those with precordial ST depression.<sup>10</sup> Similar to our findings, EL Atroush and colleagues reported significantly more frequent LAD lesion in those with reciprocal ST depression.<sup>11</sup> Karo and colleagues also found strong correlation between sum of precordial ST depression with high grade LAD lesion.<sup>12</sup> However in a study by Gibson and colleagues, there was no difference in LAD disease in between those with and without anterior ST depression.<sup>2</sup> Beside this, we did not find significant correlation of other variables like age, sex, HTN, DM, smoking, dyslipidemia, family history of CVD, LVEF, number of coronary arteries involved and culprit vessel for inferior STEMI in between those with and without anterior ST depression. Karo and colleagues also found no difference in age, sex, HTN, DM, dyslipidemia and smoking status between those with and without ST depression.<sup>12</sup> However, Namdar and colleagues found higher prevalence of DM and HTN though there was no significant difference in prevalence of smoking, hyperlipidemia and family history of coronary artery disease in between the groups.<sup>3</sup> Our finding of absence of significant difference in LVEF in between the group was in consistence with the findings of EL Atroush and colleagues.<sup>11</sup> Most of our findings were thus in consistence with several of the reported studies done previously in other settings.

This study has few limitations. It was a single centre study with limited sample size and short study duration. Changes in ECG in myocardial infarction is a dynamic process are a dynamic process. Though we analyzed the 1st ECG done in our centre, we did not consider the time interval of symptom onset to ECG recording. The time duration of onset of the event to hospital presentation could have influenced the ECG findings to some extent. We also didn't aim to see pattern of coronary dominance, characteristics and site of lesion in coronary artery, types of LAD and presence or absence of retrogrades and collaterals in the present study.

## Conclusion

Presence of ST depression in anterior leads in the patients of acute inferior myocardial infarction can be due to presence of concomitant LAD lesion. They should be dealt with special attention during their management for better outcome. We hope this study will provide ground for larger studies.

## Source of funding

None

## Conflict of interest

None

## References

1. Scirica BM, Libby P, Morrow DA. ST-Elevation Myocardial Infarction: Pathophysiology and Clinical Evolution. In: Zipes DP, Libby P, Bonow RO, Mann DL, Tomaselli GF, editors. Braunwald's Heart disease. Vol 2. 11th ed. New Delhi: ELSEVIER; 2019. p. 1095.
2. Gibson RS, Crampton RS, Watson DD, Taylor GJ, Carabello BA, Holt ND, et al. Precordial ST-segment Depression During Acute Inferior Myocardial Infarction: Clinical, Scintigraphic and Angiographic Correlations. *Circulation*. 1982;66(4):732-741. <https://doi.org/10.1161/01.CIR.66.4.732>
3. Namdar H, Imani L, Ghaffari S, Aslanabadi N, Reshadati N, Samani Z. ST-segment depression in left precordial leads in electrocardiogram of patients with acute inferior myocardial infarction undergoing primary percutaneous coronary intervention. *Interventional Medicine & Applied Science*. 2018;10(4):191-197. <https://doi.org/10.1556/1646.10.2018.19>
4. Nasmith J, Marpole D, Rahal D, Homan J, Stewart S, Sniderman A. Clinical outcomes after inferior myocardial infarction. *Ann Intern Med*. 1982;96:22-26. <https://doi.org/10.7326/0003-4819-96-1-22>
5. Hlatky MA, Califf RM, Lee KL, Pryor DB, Wagner GS, Rosati RA. Prognostic significance of precordial ST-segment depression during inferior acute myocardial infarction. *Am J Curdiol*. 1985;55: 325-329. [https://doi.org/10.1016/0002-9149\(85\)90369-8](https://doi.org/10.1016/0002-9149(85)90369-8)
6. Boden WE, Bough EW, Korr KS, Russo J, Gandsman El, Shulman RS. Inferoseptal myocardial infarction: Another cause of precordial ST-segment depression in transmural inferior wall myocardial infarction? *Am J Cardiol*. 1984;54:1216-1223. [https://doi.org/10.1016/S0002-9149\(84\)80070-3](https://doi.org/10.1016/S0002-9149(84)80070-3)
7. Bimbaum Y, Herz I, Sclarovsky S, Zlotikamien B, Chetrit A, Olmer L, et al. Prognostic significance of precordial ST segment depression on admission electrocardiogram in patients with inferior wall myocardial infarction. *J Am Coll Cardiol*. 1996;28(2):313-318. [https://doi.org/10.1016/0735-1097\(96\)00173-8](https://doi.org/10.1016/0735-1097(96)00173-8)
8. Abbas S, Riaz R, Javaid I, Hameed N. Coronary artery disease; acute inferior wall myocardial infarction with ST segment depression in anterior chest leads. *Professional Med J*. 2017;24(7):935-941. <https://doi.org/10.17957/TPMJ/17.3562>
9. Herlitz J, Hjalmarson A. Occurrence of Anterior ST Depression in Inferior Myocardial Infarction and Relation to Clinical Outcome. *Clin. Cardiol*. 1987;10:529-534.
10. Khalil MM, Rahman AF, Ahmed CM, Iqbal SM, Haque KS. Incidence of 'Precordial ST- Segment Depression' in Acute Inferior Myocardial Infarction. *University Heart Journal*. 2010;6(1):21-22. <https://doi.org/10.3329/uhj.v6i1.7185>
11. El Atroush H, Effat H, Shehata M, Emara H. Reciprocal ST segment changes in acute inferior myocardial infarction: Clinical, hemodynamic and angiographic implications. *Egyptian Heart Journal*. 2012;64:97-103. <https://doi.org/10.1016/j.ehj.2011.09.011>
12. Karo KB, Ketaren AP, Hasan R, Hasan H, Mukhtar Z, Lubis AC. Corelation Between Sum of Precordial ST Depression in Acute Inferior Myocardial Infarction with Stenosis Severity of Left Anterior Descending Artery. *Sumatera Medical Journal*. 2019;2(1):1- 9. <https://doi.org/10.32734/sumej.v2i1.712>